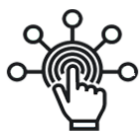

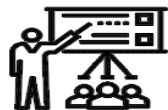SID



ابزارهای
پژوهش



سرویس ترجمه
تخصصی



کارگاه های
آموزشی



بلاگ
مرکز اطلاعات علمی



سامانه ویراستاری
STES



فیلم های
آموزشی

کارگاه های آموزشی مرکز اطلاعات علمی



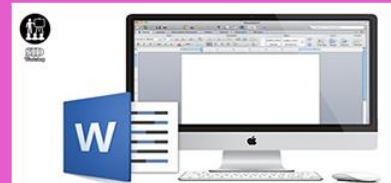آموزش مهارت های کاربردی در تدوین و چاپ مقالات ISI

آموزش مهارت های کاربردی
در تدوین و چاپ مقالات ISI



روش تحقیق کمی

روش تحقیق کمی



آموزش نرم افزار Word برای پژوهشگران

آموزش نرم افزار Word
برای پژوهشگران

Ex Vivo Evaluation of the Root Form and Root Canal Morphology of the Mandibular First Molar Using CBCT Technology

Eshagh Ali Saberi,¹ Narges Farhad-Mollashahi,*¹ Mahdi Niknami,² Elnaz Mousavi,³ Hossein Rasuli⁴

1. Department of Dentistry, Faculty of Dentistry, Zahedan University of Medical Sciences, Zahedan, Iran
2. Department of Oral and Maxillofacial Radiology, Faculty of Dentistry, Tehran Medical University, Tehran, Iran
3. Post Graduate of Endodontics, Faculty of Dentistry, Zahedan University of Medical Sciences, Zahedan, Iran
4. Department of Endodontics, Faculty of Dentistry, Ilam Medical University, Ilam, Iran

Article information	Abstract
<p>Article history: Received: 8 Feb 2012 Accepted: 7 Mar 2012 Available online: 3 June 2013 ZJRMS 2014 July; 16(7):1-6</p> <p>Keywords: Cone beam CT Canal curvature Danger zone Mandibular first molar</p> <p>*Corresponding author at: Department of Endodontics, Zahedan University of Medical Sciences, Zahedan, Iran. E-mail: nargesfarhadm@gmail.com</p>	<p>Background: This study aims to evaluate the root canal system and its curvature and the relationship between the root concavity and the dentin thickness of danger zone in the mandibular first molar using the cone beam CT method.</p> <p>Materials and Methods: A sum of 101 fresh extracted mandibular first molar were gathered and scanned by CBCT (planmeca romex 3D) machine. The root canal configuration was evaluated according to Vertucci's classification. Then, the canal curvature was evaluated according to schneider's method in clinical and proximal views. Finally, the relationship between the root concavity and the dentin thickness of danger zone was evaluated using the Pearson correlation coefficient.</p> <p>Results: The most common canal configuration of the mesial roots was vertucci type IV (49.5%), followed by type II (46.5%). Root canal configuration of the distal root revealed type I in 50.5% and type II in 27.7%. The average angles in proximal dimension for MB, ML, DB and DL canals were 18.80, 13.77, 8.22 and 16.86, respectively. These values in clinical dimension were 22.5, 21.9, 13.83 and 12.04, respectively. No meaningful relationship was found between the dentin thickness and the root concavity of danger zone.</p> <p>Conclusion: The clinician's awareness of the anatomy of the root canal system and the canal curvature and the internal and external anatomy of the root is helpful and necessary in diagnosis and treatment of the endodontic cases.</p> <p>Copyright © 2014 Zahedan University of Medical Sciences. All rights reserved.</p>

Introduction

The morphological variation and complexities of the canal, especially in the multi-rooted teeth have been always encountering serious diagnosis and treatment challenges [1]. Various laboratory studies have been conducted regarding the evaluation of the morphology of the root canal system, among which one can mention the following methods: plastic resin injection, teeth sectioning and macroscopic evaluation of the parts, evaluation through SEM, teeth evaluation using radiography and file, clearing the samples with or without the ink injection, computed tomography (CT), spiral CT, micro CT, Cone Beam CT [2-5]. Root canal morphology has been classified by Weine [6], Kuttler and Pineda [7] and Vertucci [8]. Different methods have been introduced by numerous studies for estimation of the root canal curvature [9, 10]. Schneider proposed the most reliable method for estimation of the canal curvature at clinical dimension [11]. Cunningham and Senia emphasized that the canal curvature should be evaluated at proximal dimension as well [9]. Estrela et al. during their study on the canal curvature have reported more accuracy for CBCT compared to periapical and panoramic film and reminded that the false negative results are considerably reduced by using the CBCT method [12]. Matherne

proposed that the CBCT images are helpful and precise for detection of root canal system [13]. Being aware of root surface anatomy and its concavities and the dentin thickness especially at danger zone enables the clinician to efficiently encounter those events which result in the failure of the treatment. Abou-rass, et al. were among the first persons who described the danger zone in mandibular molars and pointed out the importance and sensitivity of this region during the instrumentation [14]. Danger zone is located in mandibular molars at the distal wall of the mesial root. In a study conducted by Tabrizzadeh on the sections of the mandibular first molars, the dentin thickness of danger zone was reported to be meaningfully less than this value in other sections [15]. Park reported similar results using CBCT method [16]. Firstly, the use of CT method was introduced by Matsomoto and Tachibana for the field of endodontics [17], but wasn't taken into consideration due to the poor resolution. Then, the Micro CT was introduced as a precise tool in evaluating the root canal system [18]. The CBCT method has recently caused a revolution in diagnosing and resolving the endodontic problems and is used as a diagnostic tool for evaluating the periapical lesions, the root canal system and the root resorption. Moreover, it

eliminates the superimpositions of the anatomic structures and provides the clinician with the more predictable therapeutic strategies [19-22]. Hence, regarding the 2D nature and inherent limitations of the images of the usual radiography and considering the advanced technology of the CBCT, the high scan speed, low dose of radiation, regeneration and rapid and easy access to information, high resolution of the 3D images and non-destruction of the samples [23-26] we are going to evaluate the morphology of the root canal system, canal curvature in two clinical and proximal views, root surface concavity, dentin thickness of danger zone and the relationship between the dentin thickness and concavity of danger zone using the CBCT method in extracted mandibular first molars.

Materials and Methods

In this cross-sectional descriptive study, 101 extracted double-rooted mandibular first molar whose roots are completely developed were gathered and maintained in 10% formalin solution. Previously, the informed consent was taken from the patient regarding the providing its tooth after being extracted for use in the study. The teeth with broken roots and very narrow or blocked canals or with serious defects like the corrosion were eliminated from the study. To integrate the samples positions, the teeth were fixed in some molds made of silicone impression molding materials in 7-tooth groups and were undergone through radiation. The radiation was done by the following machine CBCT (planmeca Romexis 3D Helsinki, Finland): (S=12, mA=10, KVP=80). all the CT scanners include an X-ray source and detector which are installed on a rotating gantry. During rotation, many radiations are performed in constant time intervals which generate unique images known as reference images. Using these sectional images, some evaluations were made on the three proprietary objectives of the plan as follows:

1. Evaluation of the root canal system: with the 5× zoom in axial section along the root, the sections were selected as series from coronal to apical and the canal type for each root was determined based on Vertucci classification (Fig. 1) regarding the sequence of sections.
2. Evaluation of the root canal curvature: a) Clinical dimension: in sagittal section, an image was selected in which entire the canal length was apparent. The canal curvature was determined using the angle between two straight lines by Schneider method. The first line (L_1) begins from the orifice (point a) and is parallel to the longitudinal axis of the root canal's coronal curvature. The separation point of the line L_1 from the root canal is named point b. The second line (L_2) is drawn from apical foramen towards point b. The acute angle formed from intersection of two lines is known as angle of curvature (Fig. 2). According this angle, the canals were categorized into three groups, namely the straight ($\leq 10^\circ$), moderate ($10^\circ-20^\circ$) and severe ($20^\circ <$) groups [11].
- b) Proximal dimension: in the coronal sections, the curvatures of the mesiobuccal, mesiolingual, distobuccal

and distolingual canals were calculated (Fig. 3). Evaluation of the relationship between the root surface concavity and the dentin thickness of danger zone: three axial sections were provided from the danger zone. The first section was precisely selected below the furcation region and the third one was selected at the end of the coronal section and the second section was selected between these two sections. Then, the root concavity and the dentin thickness were measured in mm. The canal system's configuration, the number of canals, canal curvature, root dentin thickness and the depth of the root concavity were described using the central and dispersion indexes (mean, standard deviation, confidence intervals) and the Pearson correlation test was used for data analysis and evaluation of the correlation between two variables (dentin thickness and depth of root concavity) and finally, the software SPSS-15 was used to describe and analyze the data.

Results

In this study, the anatomy of the mesial and distal root canals in mandibular first molar was evaluated. Among a total of 101 teeth, the most prevalent canal systems in mesial and distal root were types IV and I according to Vertucci classification. Totally 51.5% of the samples had 3 canals, 6.3% had 4 canals and 2.2% had 5 canals. The obtained results are summarized in table 1. The curvature of the mesiobuccal, mesiolingual, distobuccal and distolingual canals in clinical and proximal dimensions (sagittal and coronal sections) are presented in tables 2 and 3 based on the Schneider method. The mean dentin thickness in distal wall of the mesiobuccal and mesiolingual canals was 1.067 and 1.014 mm respectively and the mean thickness was 1.04 mm in sum. The mean concavity of the distal surface in mesial root was evaluated in three levels (Table 4). No significant relationship was found between the mean dentin thickness of danger zone of the mesiobuccal or mesiolingual canals and the mean concavity of the root surface at the same zone (Table 5). The Pearson correlation coefficient between the mean dentin thicknesses in mesiobuccal canal in three levels and the mean depth of the root concavity in three levels was equal to 0.015 that the correlation test between these two variables wasn't significant. In this way, for mesiolingual canal the coefficient was not significant. In the root's cross section, precisely below the furcation level (section 1), the dentin thickness was reduced with the increase of the root concavity and increased in two other sections which these values weren't significant in 95% and 99% levels ($p < 0.05$).

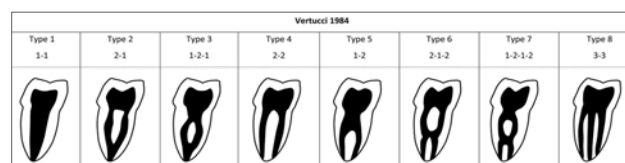


Figure 1. Classification of root canal system (Vertucci classification)

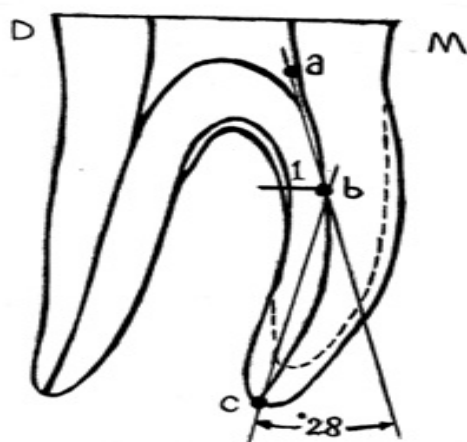


Figure 2. Schematic illustration of the method of calculating the curvature of the canal (Schneider method)

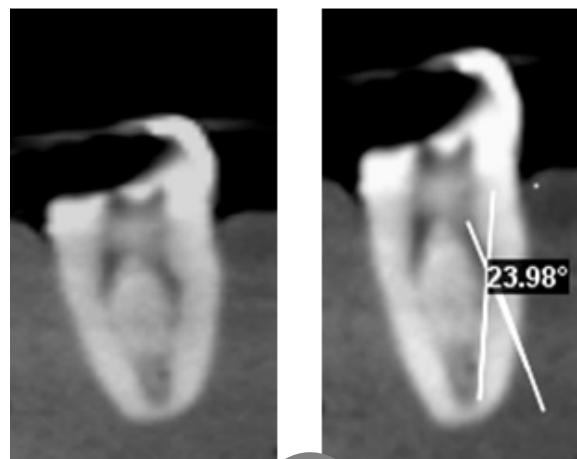


Figure 3. Coronal cross sectional view and measurement of canal curvature in the proximal dimension

Table 1. Distribution of canal number and type in mesial and distal root

	Number of canals			Type of canals (Vertucci)							
	1	2	3	1	2	3	4	5	6	7	8
Mesial root	0	98%	2%	0	46.5%	0	5.5%	0	2%	0	2%
Distal root	50.5%	49.5%	0	50.5%	29.7%	5%	10.9%	4%	0	0	0

Table 2. Mean curvature of the MB, ML, DB, DL canals from clinical and proximal view

Canals	N/valid	Mean ±SD	Variance	Range	Maximum	Minimum
P*/MB	101	18.80±7.45	55.600	36.000	7.00	43.00
p/ML	101	18.77±6.81	47.498	35.00	6.00	41.00
p/DB	101	8.22±4.73	22.478	30.00	2.00	32.00
p/DL	45	16.86±4.35	18.982	2.00	8.00	30.00
c**/MB	101	22.50±5.65	31.997	30.00	12.00	42.00
c/ML	101	21.90±5.43	29.510	28.00	14.00	42.00
c/DB	101	13.83±6.03	36.401	40.00	2.00	42.00
c/DL	45	12.04±4.58	21.043	19.00	4.00	23.00

MB=mesiobuccal/ML=mesiolingual/DB=distobuccal/DL=distolingual, P=proximal view (coronal cross section), **C=clinical view (sagittal cross section)

Table 3. Frequency distribution of canals curvature based on schneider method in clinical (c) and proximal (p) dimensions

Canal Group	MB		ML		DB		DL	
	P	C	P	C	P	C	P	C
Slight	10.9	8.9	8.9	0	75.2	29.9	8.9	33.3
Moderate	66.3	35.6	72.3	45.5	8.22	61.4	73.9	60.0
Sever	22.8	55.4	18.8	54.5	2.0	8.7	17.2	6.7

Table 4. Root concavity and dentin thickness values in danger zone in three levels

Level	Dentin thickness		Root concavity
	Mesiolingual	Mesiobuccal	
1	0.228±1.070	0.207±1.124	0.183±0.850
2	0.205±1.015	0.185±1.064	0.177±0.881
3	0.200±0.958	0.194±1.014	0.198±0.814
Mean	1.014	1.067	0.848

Table 5. Determination of the relationship between the mean of root concavity and dentin thickness in three levels using Pearson correlation coefficient

		Mean MB	Mean ML	Mean concavity
Mean MB*	Pearson Correlation	0.937 **	0.015	1
	N	101	101	101
Mean ML***	Pearson Correlation	1	0.057	0.937 **
	N	101	101	101
Mean Concavity****	Pearson Correlation	0.057	1	0.015
	N	101	101	101

*Mean MB= mean of dentin thickness in three levels in mesiobuccal root, **Correlation is significant at the 0.01 level (2-tailed), ***Mean ML= mean of dentin thickness in three levels in mesiolingual root, ****Mean Concavity= mean of root concavity in three levels

Discussion

In this study, the number of the canals, canal morphology and canal system of the 101 mandibular first molar, the root canal curvature, dentin thickness and root concavity and the relationship between the two latter items in danger zone were evaluated using the CBCT method. The results obtained for the number of the canals of the mandibular first molar suggests that more than half samples are 3-canal (51.5%), 46.3% of the cases are 4-canal and 2.2% are 5-canal. In a study conducted by Huang which was performed as in vivo using the CBCT method, 56.1% of the mandibular first molars were 3-canal and 40.5% and 3.4% of the samples were 4- and 2-canal, respectively [27]. Shahi et al. reported the prevalence of the 3-, 4- and 2-canal cases as 65.56%, 31.57% and 2.87% [28].

In a systematic review performed with regard to anatomy and configuration of the root and root canals mandibular molar, an extensive variety of research methodology is observed [29]. Neelakantan et al. evaluated seven methods for evaluation of the root canal system including the modified canal staining, clearing technique, Cone Beam CT, peripheral quantitative CT, spiral CT, plain digi and contrast medium enhanced digital and concluded that the clearing technique and the staining are applicable as gold standard methods in evaluation of the root canal morphology and the CBCT method is also a valuable method which is applicable in both the invitro and invivo approaches [30]. Mathern reported the preference of CBCT method over the charged coupled device (CCD) and photostimulable phosphor (PSP) in detection of the root canal system [12]. Blument [31] and Zheng [32] stated that the CBCT is a reliable method for finding the maxilla first molar's second mesiobuccal canal (MB₂). In our evaluation performed by CBCT method, the more common types of the canals were types IV (49.5%) and II (46.5%) respectively. Based on a systematic review, the most common configurations in mesial root were types IV and II [29]. In a study conducted by Wang, 94% of the mesial roots were of type IV which is higher than the results of the previous researches [33]. In the study of the Zaatari [34] and Al-Nazhan [35] on the mesial root canal system, the highest common rate was related to type II. In most of the studies, the incidence of the type VIII in mesial root was 0.2-5% [8, 27, 28, 32, 33]. In our study, the prevalence of the type VIII was within this interval (2.0%). These differences are justifiable regarding the design of the study (in vitro, in vivo) and the canal detection technique (CBCT or clearing). Based on different studies, the most common configuration of the distal root canal is the type I. Gu concluded that almost all the distolingual and distobuccal canals are of type I [36]. In our study, the most frequency was related to type I (50.5%) and type II (29.7%) which was similar to studies conducted by Ramesh [37], Shahi [28], Gulabivala [38] and Caliskan [39]. Regarding the high incidence of the 2-canal distal root, the change of the access form from triangular to rectangular was proposed

for finding the distolingual canal. In our study, 61.4% of the mesiobuccal canals and 54.5% of the mesiolingual canals had severe curvature at clinical dimension which was similar to studies conducted by Shaffer [10], Cunningham and Senia [9] that emphasize the use of instrumentation techniques such as anti-curvature technique, while most of the distal canals had a moderate curvature. Various studies have proposed some methods for estimation of the canal curvature using the periapical radiography. Knowledge of the canal curvature increases the planning precision for instrumentation and reduces the accident probability. In mesial roots in sagittal dimension, the canal curvature begins immediately after the orifice and goes towards the mesial and then the distal regions that this anatomic situation makes the canal prone to strip perforation. The degree of curvature in mesiobuccal and mesiolingual canals in the study of Schafer [10] were 25 and 22 degrees, respectively, and these values were 28.7 and 27.2 in the study of Cunningham and Senia [9]. In contrary to the sagittal sections, in the coronal sections the canal curvature can be easily calculated because of the lack of superimposition of the mesiobuccal and mesiolingual or the distobuccal and the distolingual canals of each other. In coronal sections, the mean value of the mesiobuccal and mesiolingual canals are 18.8 and 18.7, respectively which are similar to those obtained by Cunningham and Senia studies [9]. In the mesial root in the coronal sections, more than half of the canals had moderate curvature in contrary to the coronal sections. In coronal sections, the mean canal curvature at distobuccal and distolingual canals was 8.2 and 16.8, respectively. The higher value of the distolingual canal curvature with respect to distobuccal canal emphasizes the necessity of considering this fact in the canal instrumentation. The advantage of using CBCT rather than the radiography and file methods in canal curvature measurement is that in radiography it's likely that the file wouldn't remain in canal center. On the other hand, in some complex root canal systems or partial calcifications and/or small canals with ramification, the file and radiography methods aren't efficient and the attempts for placement of the file result in failure [12].

In our evaluation on the distal wall of the mesial root canals of mandibular first molar, the mean dentin thickness in mesiobuccal and mesiolingual canals were 1.067 and 1.014 mm, respectively and the mean size of this region was estimated to be 1.041 mm. the variation of the dentin thickness in different regions of the root is an important fact that disregarding it would result in some problems such as strip perforation. Knowledge of the dentin thickness of danger zone is necessary in order to prevent from those events which lead to the failure of the root canal treatment. Kessler [40] evaluated the dentin thickness of danger zone in mandibular molars and estimated this value to be within 1.119±0.273 mm. Lim and Stock [41] in their study on the risk of perforation in mandibular molars reported the mean size of the danger size as 1.05±0.28. Berutti and Feldon [42] reported the mean thickness of danger zone in mesiobuccal and

mesiolingual canals of mandibular molars as 1.19 and 1.25 mm, respectively which the values are similar to the results of the current study. In our study, the mean concavity of the distal wall of the mesial root in three sections was estimated to be 0.84 mm. No significant correlation was found between the mean distal concavity and the mean dentin thickness of the mesial root in danger zone and out hypothesis regarding the reduction of the dentin thickness with increase of the depth of the root surface concavity was rejected. Filho showed that the depth of the distal wall concavity in mesial root is within 0.5-0.59 mm, 0.40-0.49 mm and 0.30-0.39 mm in 13, 2 and 0.5% of the cases, respectively. They noticed in their study that the lesser the dentin thickness of danger zone and the more the concavity depth, the more would be the tooth prone to the vertical fracture [43]. Regarding this fact that most of the today instrumentation techniques are based on the preflaring, it's recommended to consider the danger zone and not to remove the dentin in this region too more than enough. Disregarding the root canal's anatomic variations, the canal curvature, the difference and variety in dentin thickness in different regions of the root can result in the failure of the endodontic treatment.

References

- Awawdeh L, Abdullah H, Al-Qudab A. Root form and canal morphology of Jordanian maxillary first Premolars. *J Endod* 2008; 34(8): 956-61.
- Sert S, Bayirli GS. Evaluation of the root canal configurations of the mandibular and maxillary permanent teeth by gender in the Turkish population. *J Endod* 2004; 30(6): 391-8.
- Martos J, Lubian C, Silveira LF, et al. Morphometric analysis of the root apex in human teeth. *J Endod* 2010; 36(4): 664-7.
- Chen G, Yao H, Tong C. Investigation of the root canal configuration of mandibular first molars in a Taiwan Chinese population. *Int Endod J* 2009; 42(11): 1044-9.
- Patel S, Dawood A, PittFord T, et al. The potential applications of cone beam computed tomography in the management of endodontic problems. *Int Endod* 2007; 40(10): 818-30.
- Weine FS. Case report: Three canals in the mesial root of mandibular first molar. *Endod* 1982; 8(11): 517-20.
- Pineda F, Kuttler Y. Mesiodistal and buccolingual roentgenographic investigation of 7275 root canals. *Oral Surg* 1972; 33(1): 101-10.
- Vertucci FJ. Root canal anatomy of the human permanent teeth. *Oral Surg Oral Med Oral Pathol* 1984; 58(5): 589-99.
- Cunningham CJ, Senia ES. A three-dimensional study of canal curvatures in the mesial roots of mandibular molars. *J Endod* 1992; 18(6): 294-9.
- Schafer E, Diez Ch, Hoppe W and Tepel J. Roentgenographic investigation of frequency and degree of canal curvatures in human permanent teeth. *J Endod* 2002; 28(3): 211-6.
- Schneider SW. A comparison of canal preparations in straight and curved root canals. *Oral Surg Oral Med Oral Pathol* 1971; 32(2): 271-5.
- Estrela C, Bueno MR, Sousa-Neto MD and Pecora JD. Method for determination of root curvature radius using cone beam computed tomography images. *Braz Dent J* 2005; 19(2): 114-118.
- Matherne RP, Angelopoulos C, Kulild JC and Tira D. Use of cone-beam computed tomography to identify root canal systems in vitro. *J Endod* 2008; 34(1): 87-9.
- Abou-Rass M, Frank AL, Glick DH. The anticurvature filing method to prepare the curved root canal. *J Amer Dent Assoc* 1980; 101(5): 792-4.
- Tabrizzadeh M, Reuben J, Khalesi M, et al. Evaluation of radicular dentin thickness of danger zone in mandibular first molars. *J Dentistry* 2010; 7(4): 196-199.
- Chang YR, Choi YS, Choi GW and Park SH. Evaluation of danger zone in mesial root of mandibular first molar by cone beam computed tomography (CBCT). *Korean J Oral Maxillofac Radiol* 2007; 37(2): 103-110.
- Tachibana H, Matsumoto K. Applicability of X-ray computerized tomography in endodontics. *Endod Dent Traumatol* 1990; 6(1): 16-20.
- Dowker SE, Davis GR, Elliott JC. X-ray microtomography: Non-destructive three dimensional imaging for in vitro endodontics studies. *Oral Surg Oral Med Oral Pathol Oral Radiol Endod* 1997; 83(4): 510-6.
- Patel S. New dimensions in endodontic imaging: part 2- cone beam computed tomography. *Int Endod J* 2009; 42(6): 463-75.
- Hashimoto K, Arai Y, Iwai K, et al. A comparison of a new limited cone beam computed tomography machine for dental use with a multidetector row helical CT machine. *Oral Surg Oral Med Oral Pathol Oral Radiol Endod* 2003; 95(3): 371-7.
- Winter A, Pollack A, Frommer H and Koenig L. Cone beam volumetric tomography vs. medical CT scanners. *N Y State Dent J* 2005; 71(4): 28-33.
- Nair MK, Nair UP. Digital and advanced imaging in endodontics: A review. *J Endod* 2007; 33(1): 1-6.
- Mozzo P, Procacci C, Tacconi A, et al. A new volumetric CT machine for dental imaging based on the cone-beam

The CBCT scans with high resolution and low radiation dose boost our capabilities in detection of various types of the root canal system and canal curvatures and more complete evaluation of the danger zone.

Acknowledgements

The present paper adopted from an Endodontics Thesis with registration number of 108-T in Zahedan University of Medical Sciences. The authors wish to thank the Research Deputy of Zahedan University of Medical Sciences for financial support of this study and also the patients participating in the study.

Authors' Contributions

All authors had equal role in design, work, statistical analysis and manuscript writing.

Conflict of Interest

The authors declare no conflict of interest.

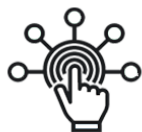Funding/Support

Zahedan University of Medical Sciences.

- technique: preliminary results. *Eur Radiol* 1998; 8(9): 1558-64.
24. Arai Y, Tammissalo E, Hashimoto K and Shinoda K. Development of a compact computed tomographic apparatus for dental use. *Dento Maxillofac Radiol* 1999; 28(4): 245-8.
 25. Araki K, Maki K, Seki K, et al. Characteristics of a newly developed dentomaxillofacial X-ray cone beam CT scanner (CB MercuRay): System configuration and physical properties. *Dentomaxillofac Radiol* 2004; 33(1): 51-9.
 26. Liedke GS, de Silveira HE, de Silveira HL, et al. Influence of voxel size in the diagnostic ability of cone beam tomography to evaluate simulated external root resorption. *J Endod* 2009; 35(2): 233-5.
 27. Huang CC, Chang YC. Evaluation of root and canal systems of mandibular first molars in Taiwanese individuals using Cone-beam computed tomography. *J Formos Med Assoc* 2010; 109(4): 303-308.
 28. Shahi S, Yavari HR, Rahimi S and Torkamani R. Root canal morphology of human mandibular first permanent molars in an Iranian population. *JODDD* 2008; 2(1): 20-23.
 29. DePablo OV, Estevez R, Peix Sanchez M, et al. Root anatomy and canal configuration of the permanent mandibular first molar: A systematic review. *J Endod* 2010; 36(12): 1919-31.
 30. Neelakantan P, Subbarao C, Subbarao CV. Comparative evaluation of modified canal staining and clearing technique, cone beam computed tomography, peripheral quantitative computed tomography, spiral computed tomography, and plain and contrast medium-enhanced digital radiography in studying root canal morphology. *J Endod* 2010; 36(9): 1547-1551.
 31. Blattner TC, George N, Lee CC, et al. Efficacy of cone-beam computed tomography as a modality to accurately identify the presence of second mesiobuccal canals in maxillary first and second molars: A pilot study. *J Endod* 2010; 36(5): 867-70.
 32. Zheng QH, Wang Y, Zhou XD, et al. A cone-beam computed tomography study of maxillary first permanent molar root and canal morphology in a Chinese population. *J Endod* 2010; 36(9): 1480-4.
 33. Wang Y, Zheng GH, Zhou XD, et al. Evaluation of the root and canal morphology of mandibular first permanent molars in a western Chinese population by Cone-beam computed tomography. *J Endod* 2010; 36(11): 1786-1789.
 34. Zaatari EI, Al-Kandari AM, Alhomaidah S and Al-Yasin IM. Frequency of endodontic treatment in Kuwait: Radiographic evaluation of 846 endodontically treated teeth. *J Endod* 1997; 23(7): 453-6.
 35. Al-Nazhan S. Incidence of four canals in root-canal-treated mandibular first molars in a Saudi Arabian sub-population. *Int Endod J* 1999; 32(1): 49-52.
 36. Gu YC, Lu Q, Wang HG, et al. Root canal morphology of permanent three-rooted mandibular first molars-part I: Pulp floor and root canal system. *J Endod* 2010; 36(6): 990-4.
 37. Ramesh Chourasla H, Meshram GK, Warhadpande M, Dakshindas D. Root canal morphology of mandibular first permanent molars in an Indian population. *Int J Dentistry* 2012; 2012: 1-6.
 38. Gulabivala N, Papanicolaou A, Ng YL and Alavi A. Root and canal morphology of the mandibular molars. *Int Endod J* 2002; 35(1): 5-12.
 39. Caliskan MK, Pehlivan Y, Sepetcioglu F, et al. Root canal morphology of human permanent teeth in a Turkish population. *J Endod* 1995; 21(4): 200-4.
 40. Kessler JR, Peters DD, Lorton L. Comparison of the relative risk of molar root perforations using various endodontic instrumentation techniques. *J Endod* 1983; 9(10): 439-47.
 41. Lim SS, Stock CJ. The risk of perforation in the curved canal: anticurvature filling compared with step back technique. *Int Endod J* 1987; 20(1): 33-9.
 42. Berutti E, Feldon G. Thickness of cementum/dentin in mesial roots of mandibular first molars. *J Endod* 1992; 18(11): 545-8.
 43. Filho PFG, Letra A, Menezes R, Carmo AMRD. Danger zone in mandibular molars before instrumentation: an in vitro study. *J Appl Oral Sci* 2003; 11(4): 324-6.

Please cite this article as: Saberi EA, Farhad-Mollashahi N, Niknami M, Mousavi E, Rasuli H. Ex vivo evaluation of the root form and root canal morphology of the mandibular first molar using CBCT technology. *Zahedan J Res Med Sci.* 2014; 16(7): 1-6.

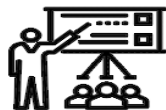SID



ابزارهای
پژوهش



سرویس ترجمه
تخصصی



کارگاه های
آموزشی



بلاگ
مرکز اطلاعات علمی



سامانه ویراستاری
STES



فیلم های
آموزشی

کارگاه های آموزشی مرکز اطلاعات علمی



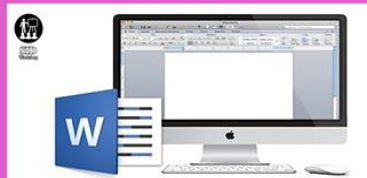تازه های آموزش
آموزش مهارت های کاربردی در تدوین و چاپ مقالات ISI

آموزش مهارت های کاربردی
در تدوین و چاپ مقالات ISI



تازه های آموزش
روش تحقیق کمی

روش تحقیق کمی



تازه های آموزش
آموزش نرم افزار Word برای پژوهشگران

آموزش نرم افزار Word
برای پژوهشگران